

Eyebrow Hair Transplantation in Frontal Fibrosing Alopecia: Pitfalls of Short- and Long-Term Results

AISTE AUDICKAITE, MD,* MAJID ALAM, PhD,*^{†‡} AND FRANCISCO JIMENEZ, MD*[†]

BACKGROUND Eyebrow hair loss is usually a primary feature of frontal fibrosing alopecia (FFA), which causes significant distress to patients and consequently seek medical help. Eyebrow hair transplantation is a well-accepted and aesthetically successful treatment, but there is a lack of information about the short- and long-term results in this subset of patients.

OBJECTIVE To report the short- and long-term eyebrow hair transplantation results in patients with FFA.

PATIENTS AND METHODS Ten patients diagnosed with FFA underwent eyebrow hair transplantation. The transplanted hairs were harvested from nonaffected follicles of the occipital scalp skin. On average, 120 to 270 single-hair follicles were implanted per eyebrow.

RESULTS Eighty percent of patients achieved excellent hair growth at 6- to 12-month follow-up and satisfactory short-term results (<2 years). However, majority started losing the transplanted hairs after 3 to 4 years. Only 1 patient did not lose transplanted hair in the long-term follow-up (>4 years).

CONCLUSION The results of eyebrow hair transplantation in FFA patients are variable and contentious. The short-term outcome is satisfactory, but in most patients, a progressive loss of transplanted hairs can be expected. Therefore, FFA patients inquiring about eyebrow transplantation should be advised about the high possibility of hair graft loss over time.

The authors have indicated no significant interest with commercial supporters.

Frontal fibrosing alopecia (FFA) is classified as an inflammatory cicatricial alopecia which typically presents as a progressive recession of the frontotemporal hairline and eyebrow loss. It affects mainly postmenopausal women, although it may also occur in younger women as well as in men.¹ During the 1990s, FFA was considered to be a rare disease, but over the past 20 years, it has become increasingly common.^{2–5} The pathophysiology of FFA involves a depletion of the bulge epithelial hair follicle stem cells along with epithelial–mesenchymal transition features on a background of hair follicle immune privilege collapse, eventually resulting in permanent hair follicle destruction and replacement with fibrous tissue.⁶ Frontal fibrosing alopecia may be associated with genetic, hormonal, and environmental factors.⁷ Among the external factors, daily facial sunscreen use

has been reported as a possible triggering factor in patients with FFA.⁸ Recent investigations suggest that FFA may be a genetically predisposed immune-inflammatory disorder driven by the HLA-B*07:02 allele.⁹

Eyebrow loss occurs in about 80%^{4,10} of FFA cases and is usually the main reason for consultation because of the significant distress and negative impact on the patient’s facial appearance. In some FFA patients, eyebrow loss can be the first and only clinical sign, providing an opportunity for early diagnosis and treatment.¹⁰

Regarding therapy of eyebrow loss, many FFA patients camouflage their eyebrows with tattooing or drawing makeup, and many enquire about the

*Mediteknia Dermatology and Hair Transplant Clinic, Las Palmas de Gran Canaria, Spain; [†]University Fernando Pessoa Canarias, Las Palmas de Gran Canaria, Spain; [‡]Monasterium Laboratory, Münster, Germany

© 2019 by the American Society for Dermatologic Surgery, Inc. Published by Wolters Kluwer Health, Inc. All rights reserved.
ISSN: 1076-0512 • Dermatol Surg 2019;00:1–6 • DOI: 10.1097/DSS.0000000000002207

possibility of hair transplantation. Although eyebrow hair transplantation is a well-accepted procedure with excellent long-term cosmetic outcomes indicated for patients with eyebrow loss due to trauma (burns, postsurgical scars, etc.), excessive plucking, or simply for the aesthetic desire of gaining more hair,¹¹ to the best of the authors knowledge, there are no published reports about its efficacy in patients with FFA. The aim of this article is to present the results of a series of 10 FFA patients who underwent eyebrow hair transplantation with a view to helping to define the guidelines of this kind of therapy in such patients.

Methods

The authors describe 10 patients (9 women and 1 man) diagnosed with FFA with eyebrow hair loss who agreed to undertake eyebrow hair transplantation. All patients were informed about the procedure of eyebrow hair transplantation and warned about the possibility of hair growth failure given the inflammatory nature of the disease. Nevertheless, all the patients opted to undertake the surgical operation with written, signed consent. Patients ranged from 28 to 58 years of age, and the onset of the disease varied from 2 to 10 years. Patients had other clinical FFA signs such as frontal line recession, temple and sideburn alopecia, and noninflammatory facial papules. All patients were using facial sunscreen, half of them daily and the other half infrequently that is when going to the beach. Most of the patients had been on a variety of medications including topical steroids, intralesional triamcinolone, or systemic treatment (finasteride, dutasteride, and chloroquine).

Transplantation was performed under local anesthesia using 0.5% lidocaine with adrenaline 1:200,000. The anesthetic solution was injected using a 25-G blunt microcannula (Pix L, Thiebaud, France) to minimize pain, as described elsewhere.¹² The transplanted hairs were harvested from the occipital scalp from an area clinically not affected by the disease. The harvesting was performed either by excising a small strip of scalp skin with a scalpel (strip harvesting technique) or by the follicular unit extraction (FUE) technique using an automated device with a punch size of 0.9 mm (WawFUE system; Devroye instruments, Brussels, Belgium). With both harvesting techniques, the FUs were microdissected into single hair follicles under a stereomicroscope and kept in physiologic saline until their transplantation into the eyebrows using 0.6-mm implanters (Lion; Hans Biomed, Seoul, Korea) (Figure 1). Approximately 120 to 270 single hair follicles were implanted per eyebrow. Detailed information on the procedure of each patient is given in Table 1.

Results

A total of 8 of the 10 patients achieved what was considered normal (80%–100%) hair growth at 6 to 12 months after transplantation, whereas 2 patients had initially unsatisfactory (50%–60%) hair growth at their 6- to 12-month follow-up (Figure 2). Of those 8 patients with an initial satisfactory growth, all kept most of their transplanted hairs up to 24 months after the procedure. Of the 8 patients who responded satisfactorily, 4 could be followed up for more than 3 years. Of these 4 patients, 3 began to lose the

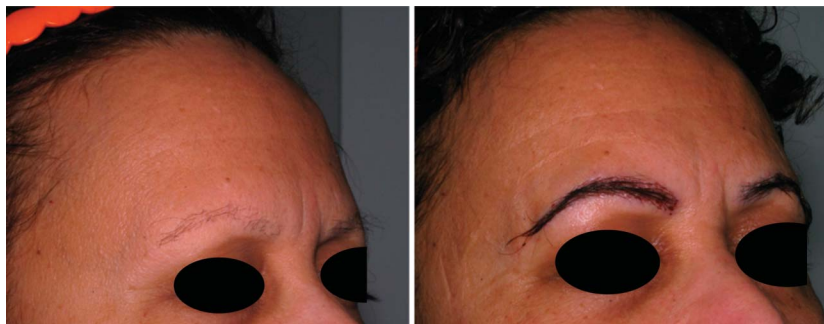

Figure 1. Eyebrow hair transplantation in FFA patients. Eyebrow hair transplantation of an FFA patient suffering from complete eyebrow loss (left) before and immediately 24 hours after (right) the procedure. Hair grafts were harvested from the occipital scalp followed by implantation of single hair follicle grafts with implanters into the eyebrows. FFA, frontal fibrosing alopecia.

TABLE 1. Treatment of Patients Diagnosed With Frontal Fibrosing Alopecia (FFA)

<i>Patient (Age, Gender)</i>	<i>Onset of FFA</i>	<i>Affected % of Eyebrows</i>	<i>No. of Transplantation Sessions, Transplantation Technique FUE, FUT</i>	<i>Other Clinical Signs</i>	<i>No. of Grafts (No. of Sessions)</i>	<i>Medications</i>	<i>Follow-up (Growth, Lost Hair (%))</i>
28 y.o. male	5 yrs	90%	FUE (0.9-mm punch)	Facial noninflammatory papules beard, moustache alopecia	FU-553 (FU 1–473, FU 2–80) Hairs-633	Tacrolimus 0.1%	After 6 mo, 80%–100% growth After 2 yrs, lost 20%–30% After 3 yrs, lost 50%
46 y.o. female	5 yrs	80%	1st FUT	Frontal hairline recession	1st FU-248 (FU 1–240, FU 2–8), hairs-256	Dutasteride 0.5 mg	After 6 mo, 80%–100% growth
			2nd FUT	Axillary, pubical, and sideburns alopecia	2nd FU-316, hairs-316	Tacrolimus 0.3% Steroid injections	After 3 yrs, lost 10%–20% After 4 years, lost 70% After 5 yrs, lost 80%
58 y.o. female	2 yrs	90%	FUE (0.9-mm punch)	Alopecia in the temple and sideburn area	FU-406 (FU 1–386, FU 2–20), hairs-426	Dutasteride 0.5 mg Topical steroids (betamethasone) Minoxidil (solution) 5%	After 6 mo, 80%–100% growth After 2 years, lost 10%–20% The patient undergoing chemotherapy for breast cancer, lost all hair
52 y.o. female	4 yrs	90%	FUE (0.9-mm punch)	Frontal hairline recession, active lesions in frontal hairline	FU-327, hairs-327	Tacrolimus 0.1% Finasteride 5 mg Dercutane 10 mg Tacrolimus 0.3% Dutasteride 0.5 mg Hydroxychloroquine 200 mg	After 6 mo, 80%–100% growth After 1 yr, lost 10%
60 y.o. female	Unknown	90%	FUE (0.9-mm punch)	Frontal hairline recession	FU-309 (FU 1–280, FU 2–29), hairs-338	Minoxidil 5% (foam)	Patient has trombophilia Poor growth after 6 mo (50%–60%) After 1 yr, lost 80%

TABLE 1. (Continued)

<i>Patient (Age, Gender)</i>	<i>Onset of FFA</i>	<i>Affected % of Eyebrows</i>	<i>No. of Transplantation Sessions, Transplantation Technique FUE, FUT</i>	<i>Other Clinical Signs</i>	<i>No. of Grafts (No. of Sessions)</i>	<i>Medications</i>	<i>Follow-up (Growth, Lost Hair (%))</i>
43 y.o. female	5 yrs	80%	1st FUT	Temples, sideburns retroauricular alopecia	1st FU-390 (FU 1-314, FU 2-76), hairs-466	Steroid injections	After 6 months, 80%–100% growth
			2nd FUT	All body hair, except pubic alopecia	2nd FU-173, hairs-173	Topical steroids (betamethasone) dutasteride 0.5 mg Tacrolimus 0.01% Estrogen solution	After 2 yrs, lost 50%
35 y.o. female	1 yr	80%	1st FUT	Frontal hairline recession, facial noninflammatory papules	1st FU-295 (FU 1-244, FU 2-51), hairs-346	Hydroxychloroquine 200 mg	After 6 months, 80%–100% growth
			2nd FUT		2nd FU-114, (FU 1-82, FU 2-32) hairs-146	Steroid injections dutasteride 0.5 mg Doxycycline 100 mg Tacrolimus 0.3%	After 4 yrs, lost 20%
47 y.o. female	6 yrs	80%	1st FUE	Pubic and axillary alopecia	1st FU-331 (FU 1-331)	Bimatoprost 0.03% (solution)	After 6 mo, 80%–100% growth
			2nd FUE (0.9-mm punch)		2nd FU-287, (FU 1-287)		After 1.5 yrs—lost 20%–30% After 2 yrs—lost 30%–40% After 3 yrs—lost 70%–80%
49 y.o. female	10 yrs	80%	FUT	Frontal hairline recession temples and sideburns alopecia	FU-386, (FU 1-386)	Hydroxychloroquine 200 mg Dutasteride 0.5 mg Pimecrolimus Minoxidil 5% (solution)	After 6 mo, 80%–100% growth 8 mo after—no hair loss
57 y.o. female	Unknown	80%	FUT	Frontal hairline recession, temples, and sideburns alopecia	FU-306 (FU 1-200, FU 2-106), hairs-412	No treatment	Poor growth after 6 mo 50%–60% growth After 2 yrs, lost all eyebrows

FUT, follicular unit transplantation; FUE, follicular unit extraction; FU, follicular unit.

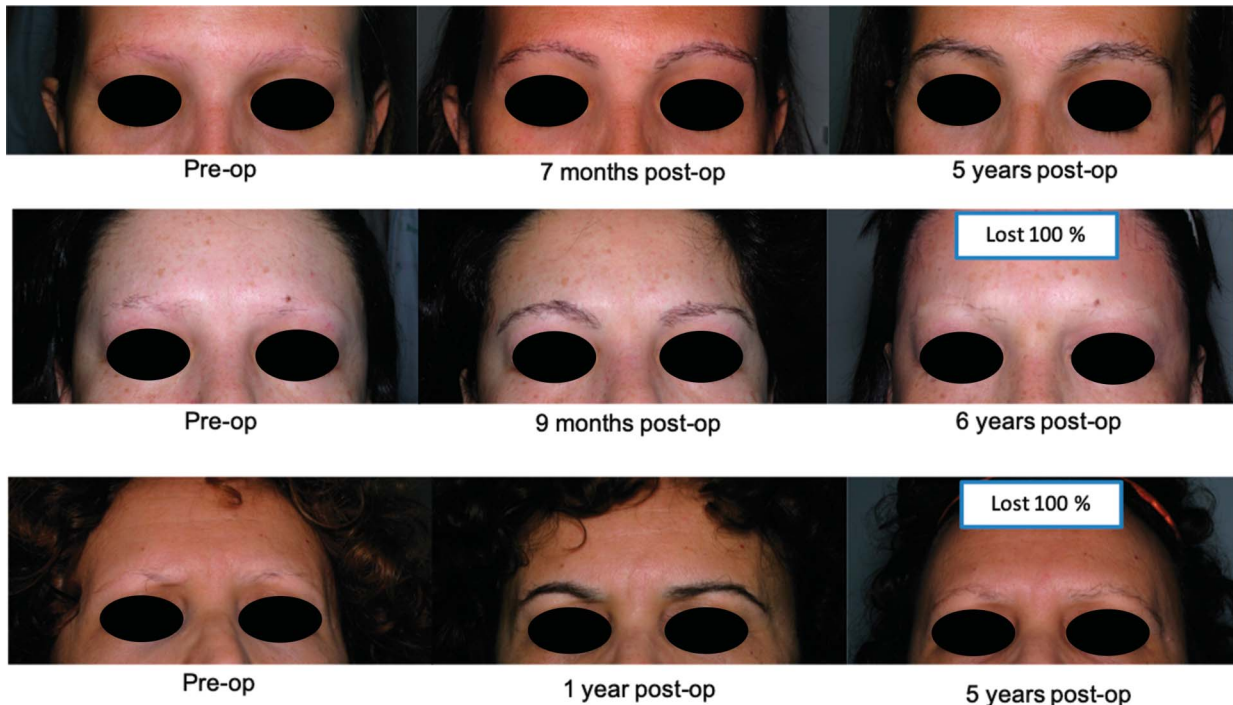

Figure 2. Short- and long-term results of hair graft transplantation in the eyebrows of FFA patients. Representative images of 3 patients suffering from FFA treated with hair transplantation. Top: A patient was transplanted with 295 hair grafts in the eyebrow area. Seven months after the procedure, the patient had lost ~10% of transplanted hair grafts and after 5 years retained ~80% of hair grafts. Middle: 390 hair grafts were transplanted, and after a 9-month follow-up, all transplanted hair grafts had been retained. However, after 6 years, all hair grafts had been lost. Bottom: 1 year after transplantation of 256 hairs, the patient had retained all grafts. However, after 5 years, all transplanted hair grafts had been lost. FFA, frontal fibrosing alopecia.

transplanted eyebrow hairs in a slow but progressive manner (Figure 2). Only 1 patient was considered to have a good long-term outcome after 4 years (Figures 2 and 3). Interestingly, some patients, despite the long-term failure, were so satisfied with the short-term results that they opted to have another hair transplant session than another form of therapy (e.g., tattooing). One patient was diagnosed with breast cancer, treated with chemotherapy and lost all body hair including transplanted eyebrows. Overall, short- and long-term outcomes were similar in most patients, retaining transplanted hair grafts in the short term and losing them in the long term (Figure 3).

Discussion

Because FFA is a primary cicatricial alopecia, there are controversial opinions about whether hair transplantation is indicated in these patients. The current belief is to first choose a medical treatment (topical or systemic) to keep the disease under remission and to only consider hair transplantation when the disease has been nonactive for at least 2 years.¹³ However, this strategy is still under debate for several reasons: first, there is no clinical or biological marker sensitive and accurate enough to ensure the disease has stabilized; second, there are cases where the trauma induced by the hair transplantation may actually stimulate or activate the disease¹⁴; and third,

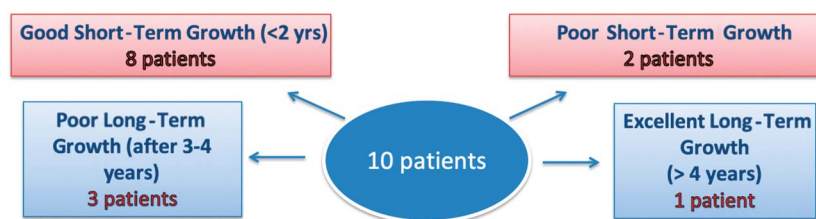


Figure 3. Schematic summarizing the outcomes of hair growth after follicular unit transplantation in the eyebrows of 10 patients suffering from FFA. FFA, frontal fibrosing alopecia.

the natural history of FFA involves long periods of remission and reactivation, and one never can be sure that the period of apparent inactivation is permanent. For these reasons, the decision to transplant a so-called “nonactive” FFA should always be made with extreme caution, with the most reasonable approach being to perform a test graft in a small area and wait 3 to 4 years to see and follow-up the results.

Although there are no published reports of eyebrow transplantation in FFA patients, it is logical to think that the results would be comparable with those when transplanted in the frontal area of FFA patients. A brief summary of such reports reveals conflicting results with both positive and negative outcomes. In some reported cases, the follow-up period of only 2 years after surgery¹⁵ is insufficient to evaluate the long-term outcome. In some other reported cases, the disease has remained absent even after 4 to 6 years.^{16,17} By contrast, Nusbaum and colleagues¹⁸ and Jimenez and colleagues¹⁹ have described cases in which initial hair growth up to 15 months after transplantation was followed by a progressive disappearance of almost all transplanted grafts after 4 to 5 years. Interestingly, a biopsy taken from one of the remaining transplanted follicles in the recipient area showed typical histologic features of FFA,¹⁹ which suggests that either FFA is a recipient dominant condition or that the transplanted grafts harvested from an apparently safe and nonaffected donor area could have been already affected but with no visible or dermoscopic signs of clinical involvement.

In summary, the authors have identified that short-term (less than 2 years) results after eyebrow hair transplantation in FFA patients are almost always satisfactory, whereas the long-term results (after 3–4 years) are almost always poor. Despite the poor long-term results, the rapid improvement in their facial appearance, self-confidence, and esteem after the eyebrow transplant explains why some patients were willing to repeat the hair transplant procedure. Transplantation of hair grafts to the eyebrows of those suffering from FFA is therefore a viable option, provided the patient is informed about the probable long-term failure. It is important to follow-up long-term results as short-term graft survival success does not guarantee the permanent survival and growth of the transplanted hair.

References

1. Kossard S. Postmenopausal frontal fibrosing alopecia. Scarring alopecia in a pattern distribution. *Arch Dermatol* 1994;130:770–4.
2. Chen W, Kigitsidou E, Prucha H, Ring J, et al. Male frontal fibrosing alopecia with generalised hair loss. *Australas J Dermatol* 2014;55:37–9.
3. Lyakhovitsky A, Barzilai A, Amichai B. Frontal fibrosing alopecia update. *World J Dermatol* 2015;4:33–43.
4. Vano-Galvan S, Molina-Ruiz AM, Serrano-Falcon C, Arias-Santiago S, et al. Frontal fibrosing alopecia: a multicentre review of 355 patients. *J Am Acad Dermatol* 2014;70:670–8.
5. Vano-Galvan S, Saceda-Corralo D, Moreno-Arrones OM, Camacho-Martinez FM. Updated diagnostic criteria for frontal fibrosing alopecia. *J Am Acad Dermatol* 2018;78:21–2.
6. Harries MJ, Jimenez F, Izeta A, Hardman J, et al. Lichen planopilaris and frontal fibrosing alopecia as model epithelial stem cell diseases. *Trends Mol Med* 2018;24:435–48.
7. Jimenez F, Harries M, Poblet E. Frontal fibrosing alopecia: a disease fascinating for the researcher, disappointing for the clinician and distressing for the patient. *Exp Dermatol* 2016;25:853–4.
8. Aldoori N, Dobson K, Holden CR, McDonagh AJ, et al. Frontal fibrosing alopecia: possible association with leave-on facial products and sunscreens; a questionnaire study. *Br J Dermatol* 2016;175:762–7.
9. Tziotzios C, Petridis C, Dand N, Ainali C, et al. Genome-wide association study in frontal fibrosing alopecia identifies four susceptibility loci including HLA-B*07:02. *Nat Commun* 2019;10:1150.
10. Anzai A, Donati A, Valente NY, Romiti R, et al. Isolated eyebrow loss in frontal fibrosing alopecia: relevance of early diagnosis and treatment. *Br J Dermatol* 2016;175:1099–101.
11. Klingbeil KD, Fertig R. Eyebrow and eyelash hair transplantation: a systematic review. *J Clin Aesthet Dermatol* 2018;11:21–30.
12. Jimenez F. Blunt needles (microcannulae) for infiltrating local anesthetics. *Dermatol Surg* 2012;38:511–2.
13. Ekelem C, Pham C, Atanaskova Mesinkovska N. A systematic review of the outcome of hair transplantation in primary scarring alopecia. *Skin Appendage Disord* 2019;5:65–71.
14. Donovan J. Lichen planopilaris after hair transplantation: report of 17 cases. *Dermatol Surg* 2012;38:1998–2004.
15. Scribel M, Dutra H, Trueb RM. Autologous hair transplantation in frontal fibrosing alopecia. *Int J Trichology* 2018;10:169–71.
16. Liu YS, Jee SH, Chan JL. Hair transplantation for the treatment of lichen planopilaris and frontal fibrosing alopecia: a report of two cases. *Australas J Dermatol* 2018;59:118–22.
17. Gurfinkiel A, Igarza HC, Casas J, Kaminsky A. Trasplante capilar en una paciente con alopecia fibrosante frontal asociada con liquen escleroatrofico de vulva. *Dermatol Argent* 2011;17:110–5.
18. Nusbaum BP, Nusbaum AG. Frontal fibrosing alopecia in a man: results of follicular unit test grafting. *Dermatol Surg* 2010;36:959–62.
19. Jimenez F, Poblet E. Is hair transplantation indicated in frontal fibrosing alopecia? The results of test grafting in three patients. *Letters and Communications* 2013;39:7.

Address correspondence and reprint requests to: Francisco Jimenez, MD, Mediteknia Dermatology and Hair Transplant Clinic, Av. Alcalde Jose Ramirez Bethencourt, 20, Las Palmas de Gran Canaria 35004, Spain, or e-mail: fjimenez@mediteknia.com